

# SKIN MARKING PROTOCOLS IN DIGITAL MAMMOGRAPHY

by Gary J. Whitman, M. D.

Associate Professor of Radiology and Associate Radiologist - Division of Diagnostic Imaging  
The University of Texas M. D. Anderson Cancer Center (UTMDACC), Houston, Texas

In screening and diagnostic mammography, optimal technique and appropriate positioning are essential. In addition, skin marking protocols are particularly helpful. At The University of Texas M. D. Anderson Cancer Center (UTMDACC), we use five different skin markers in our daily digital and screen-film mammography practice. While skin markers have been shown to provide added value in screen-film mammography, we believe that skin marking protocols are efficacious in digital mammography as well.

At UTMDACC, our skin marking protocols are identical for screen-film and digital mammograms. In our practice, we believe that skin marking protocols are an integral part of providing high quality mammographic services to our patients.

Moles and surgical scars are routinely marked by our technologists on screen-film and digital images, as these skin lesions may not be

readily apparent to the interpreting mammographer. Nipple markers are useful in digital and screen-film mammography. The placement of nipple markers facilitates accurate measurement of the nipple-to-lesion distance. Nipple markers are particularly helpful in cases in which the nipple is not in profile, in cases with subareolar masses, and in cases with suboptimal exposures. Regarding marker placement prior to stereotactic core biopsy, all of these marking procedures are performed with digital imaging guidance at UTMDACC, as digital systems allow for visualization of the marker seconds after an exposure is obtained. At UTMDACC, all palpable areas are marked. This allows the radiologist to focus on the area of interest, and tangential views are usually obtained in the region of the marker.

## NIPPLE MARKERS

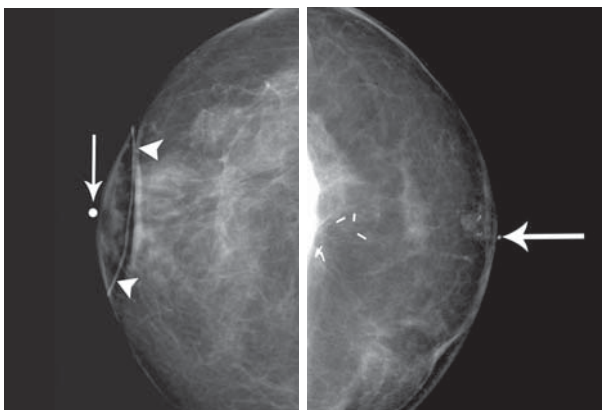


Figure 1  
An 80 year-old-woman with a history of ductal carcinoma in situ treated with segmental resection and radiation therapy underwent follow-up digital mammography. The right craniocaudal mammogram shows a nipple marker (arrow). The surgical scar is noted with a linear marker (arrowheads).

Figure 2  
A 42 year-old-woman with a history of ductal carcinoma in situ underwent a left mastectomy, followed by transverse rectus myocutaneous flap reconstruction. A left craniocaudal mammogram was performed as part of a screening examination. A nipple marker (arrow) is noted, indicating the site of the reconstructed nipple. Calcifications are noted at the nipple reconstruction site.

At UTMDACC, a marker is placed on the nipple on every mammographic image. The nipple marker (Figures 1 and 3) aids the mammographer in determining if the image was taken with the nipple in profile. If the nipple is not in profile, the nipple marker will project over the breast parenchyma. If the nipple is in profile, the marker (Figure 2) will be seen just anterior to the front of the breast. At UTMDACC, all findings on breast imaging studies (mammography, sonography, and magnetic resonance imaging) are reported with the distance from the nipple and the o'clock position. This reporting system helps to establish concordance between findings identified with different modalities.

Nipple markers continue to provide benefit on digital mammographic studies, as the radiologists can quickly and accurately determine the nipple-to-lesion distance. In digital mammography, placement of nipple markers eliminates the need to adjust the window and the level settings. Also, placement of nipple markers facilitates measurement of the posterior nipple line and aids technologists in measuring the distance from the nipple for additional views, such as spot compression and magnification views.

## SCAR MARKERS

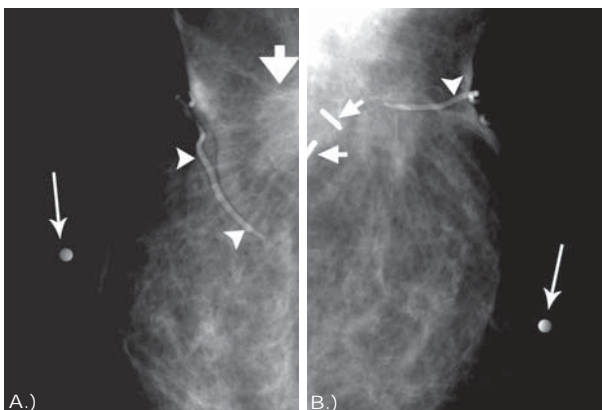
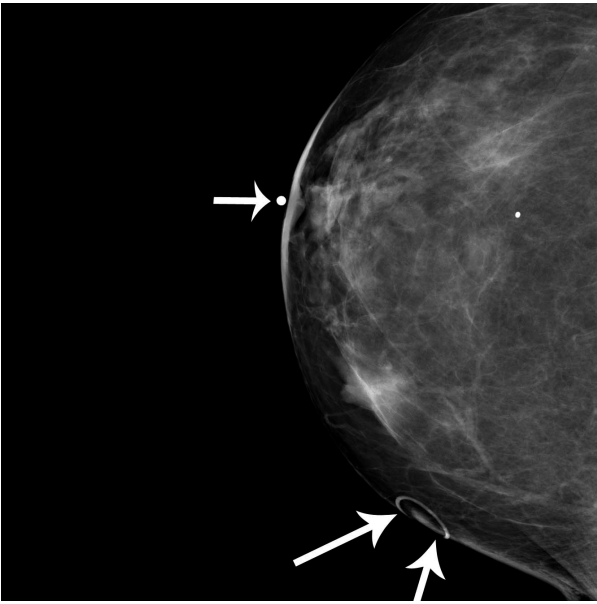


Figure 3  
A 73 year-old-woman with a history of invasive ductal carcinoma treated with segmental resection, radiation therapy, and five years of tamoxifen therapy underwent follow-up digital mammography. A.) Magnified left mediolateral mammogram shows a nipple marker (long arrow). The skin scar is noted with a linear marker (arrowheads), anterior to the scarring within the breast (short arrow). B.) Magnified left mediolateral oblique mammogram shows a nipple marker (long arrow). The surgical scar, which extends from the skin to the surgical clips (short arrows) is noted with a linear marker (arrowhead).

At UTMDACC, all surgical scars are marked with linear scar markers (Figures 1 and 3). Marking the scar aids the mammographer and the technologist in focusing on the surgical site. Often, magnification images are obtained in the region of the surgical site. The scar marker helps the radiologist to identify the surgical site within the breast. Placement of scar markers facilitates the establishment of concordance between the surgical history and the mammographic findings. All surgical scars are marked in our practice, regardless of the imaging system. Marking surgical scars is important, as it is quite common for the skin scar to be distant from the scar within the breast.

## MOLE MARKERS



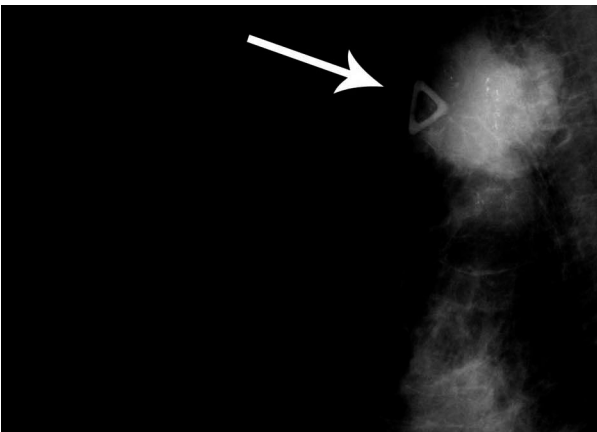
**Figure 4**

A 61 year-old-woman with a history of left breast invasive ductal carcinoma treated with segmental resection, radiation therapy, and chemotherapy underwent follow-up digital mammography. The right craniocaudal mammogram shows a nipple marker (short arrow). A mole is noted with a circular mole marker (long arrows).

At UTMDACC, markers are placed over moles and raised skin lesions. The placement of mole markers is very helpful as moles produce soft tissue densities (Figure 4) on mammography, which may be indistinguishable from lesions within the breast. When a mole marker is noted projecting over a lesion, the mammographer can confidently dismiss the lesion in question as a dermal lesion. Mole markers are particularly beneficial when films from outside institutions are reviewed and in conference situations. Also, mole markers are helpful when the images are used to compare to subsequent mammograms.

As in screen-film mammography, accurate placement of mole markers in digital mammography is crucial. Without mole markers, the mammographer would be unable to determine if the lesion was on the skin or in the breast. Furthermore, with post-processing in digital mammography, the skin line is usually seen more clearly than in screen-film mammography. Thus, one may be able to see the skin marker and the associated skin lesion with digital imaging.

## MASS MARKERS



**Figure 5**

A 51 year-old-woman presented to her physician with a palpable abnormality in the upper outer right breast. A triangular marker (arrow) was placed on the palpable abnormality on the right mediolateral oblique mammogram. A mass, with pleomorphic calcifications, noted immediately posterior to the marker, represented the palpable abnormality. The patient underwent ultrasound-guided core biopsy of the right breast mass, and pathology showed invasive ductal carcinoma.

We place triangular markers over all palpable abnormalities at UTMDACC. In addition to standard views, we obtain a view with the palpable abnormality and the marker in tangent. Marking palpable abnormalities helps to direct the technologist and the mammographer to the region of concern. Furthermore, the marker can be used to verify that the palpable area is included on the mammograms. All palpable abnormalities are marked on screen-film as well as digital studies (Figure 5). In addition, markers can help to direct sonographic evaluation of the appropriate area.

## MARKER PLACEMENT PRIOR TO STEREOTACTIC CORE BIOPSY

Prior to stereotactic core needle biopsy of faint calcifications, a surface marker may be placed over the area in question to facilitate targeting. At UTMDACC, patients with faint calcifications who are scheduled for stereotactic core biopsy are taken to a digital mammography room. An image of the calcifications scheduled for biopsy is then obtained with a fenestrated compression device. After the calcifications are identified, a radiopaque marker is placed on the skin surface, over the calcifications. The patient is then taken to the stereotactic biopsy room. A scout image is then obtained,

targeting the radiopaque marker. The associated targeted calcifications are then usually identified with little difficulty. Thereafter, the surface marker is removed, and the stereotactic core biopsy is performed. While marker placement prior to stereotactic core biopsy can be performed with screen-film mammography, this procedure should be performed with a digital system, if available. Digital mammography provides an image of the marker seconds after the exposure, resulting in decreased compression time and decreased procedure time compared to screen-film mammography.