

# LOCALIZATION OF AN AREA OF CONCERN SEEN ON ONLY ONE VIEW IN MAMMOGRAPHY

Methodology and Drawings submitted by:

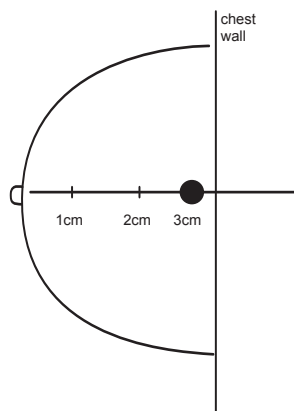
William R. Acker M.D. • Chairman and Medical Director-Medical Imaging • CIGNA Healthcare of Arizona

Very often in Mammography there is a suspicious area of concern that can only be appreciated in one view. To determine the location of this suspicious area on the second view, Radiologists have devised methods that identify a plane of possibility where the lesion could be located. These methods help to define an area where the lesion is probably located thereby reducing read time.

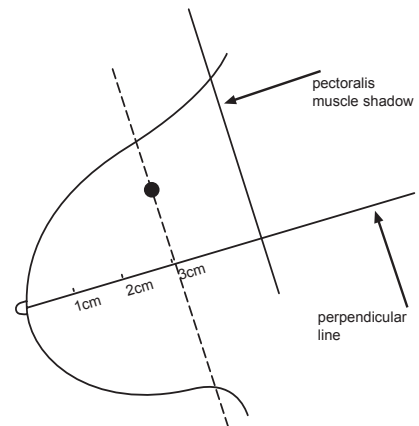
There are two methods typically used today; the Arc method and the Right angle or Cartesian methods are described below. Both of these methods benefit from the placement of a nipple marker prior to the exam. The Cartesian method has proved to be more accurate for lesions on the periphery of the breast while both methods are helpful for central lesions.

## 1. Cartesian Method (preferred method)

This right angle technique works well for central lesions and is a more reliable technique for localizing peripheral lesions seen on only one view. The Radiologist first uses a nipple marker to help establish a perpendicular nipple pectoral line on both the CC and the MLO views. Then measure from the nipple marker to the area of concern and transfer this measurement to the projection where the lesion is not immediately appreciated (*Diagram 1 and 2*).

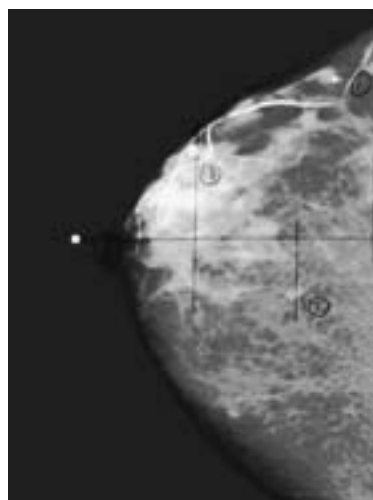


1. R-CC

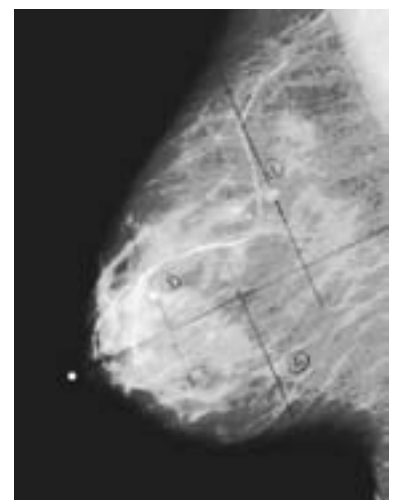

2. R-MLO

The value of this technique can be seen in Image A and B where the lesions noted in the CC view at 40mm, 70mm and 95mm are all found at the same distance in the MLO view. This holds true even for the two more peripheral findings.



A. R-CC



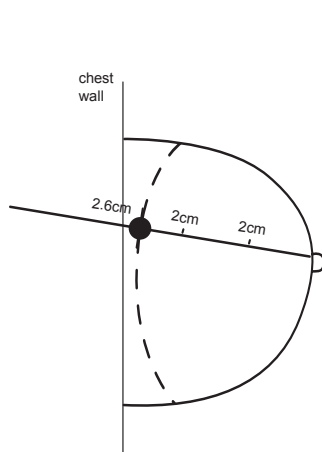
B. R-MLO

### Guidelines:

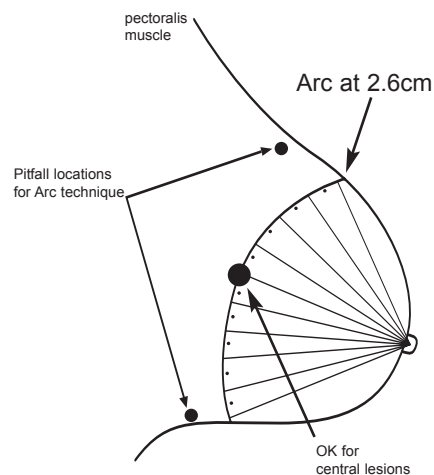
To locate lesion in 2nd view draw a line through the nipple and perpendicular to chest wall in each view. Locate depth along that line.

## 2. Arc Method

To utilize this method the Radiologist locates the nipple, or preferably the nipple marker, and measures the distance to the area of concern in the projection where the lesion is noted. In the projection where the lesion is not evident an arc is established at the distance measured in the first projection (*Diagram 3 and 4*).

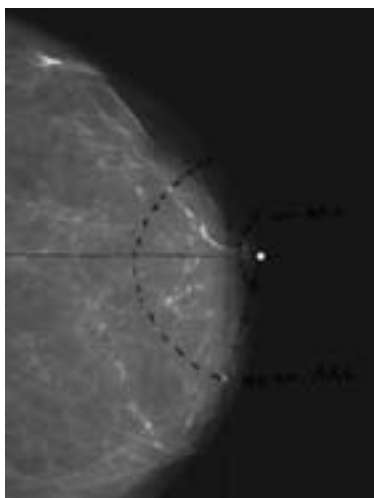


**3. L-CC**

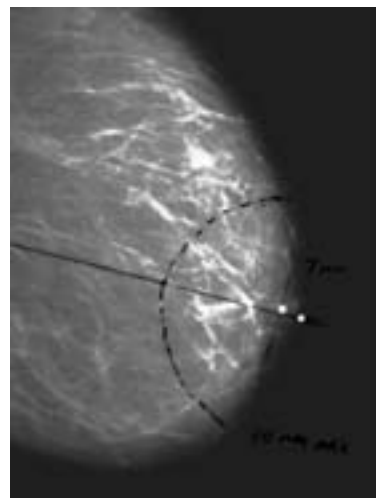


**4. L-MLO**

This method will work well for central lesions but is not accurate for peripheral lesions of the breast. Image C and D demonstrate this well, as the lesion noted in the retroareolar area in the MLO view at 7mm is found in the CC view at 40mm.



**C. L-CC**



**D. L-MLO**

**Guidelines:**

*To locate lesion in 2nd view swing an arc through the lesion from the nipple.  
Repeat in second view.*

In conclusion, the Right angle/Cartesian technique is the more consistent and most precise method. The Arc technique is fairly accurate for central lesions, but can be a pitfall for lesions at the periphery of the breast in the subareolar area, or in the axilla. These quick techniques are generally helpful for a basic approximation.