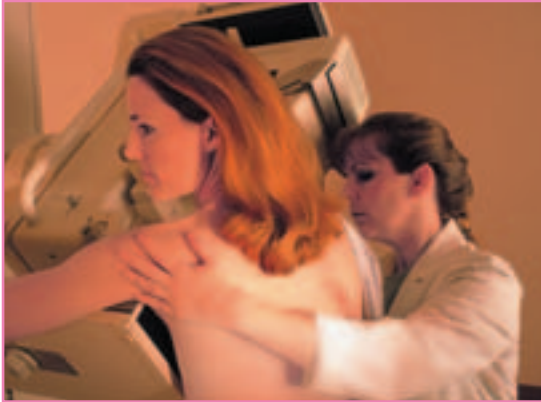

PROPER POSITIONING WITH THE USE OF NIPPLE MARKERS

By Susan Sprinkle-Vincent, A.A.S., R.T. (R) (M) Mammography Program Manager and Consultant
Advanced Health Education Center • Houston, Texas



Mammography is the most difficult radiographic procedure to perform. Studies have shown that more breast cancers were missed when a woman was not in the correct position during her mammogram. Proper positioning is the key element to ensure the greatest amount of breast tissue is captured on the clinical image. The nipple plays a key role in determining if the breast is positioned properly. During positioning the nipple can change direction at any point and may not always be able to be visualized by the technologist. As we use our hands to mobilize, capture and secure the tissue prior to compression, often times this specific hand maneuver obscures visualization

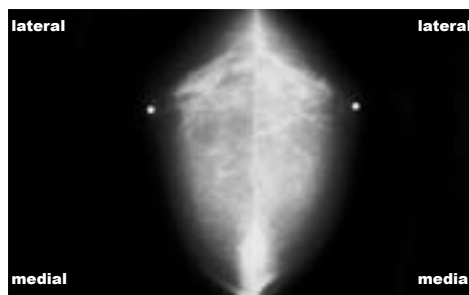
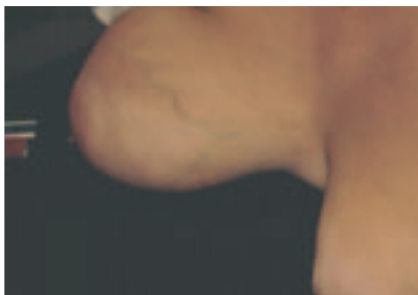
of the nipple. Using a nipple marker makes positioning easier as the marker can be felt to determine if the nipple is centered or rotated while positioning. Because we use our hands in this manner it is important to use a quality nipple marker that stays in place and does not move or come off when positioning, otherwise later we find the nipple marker on the sleeve of our scrubs, the bucky or on our shoes. A nipple marker immediately identifies the nipple location on the clinical image and is necessary on each and every patient during a mammogram. With consistent use, the marker will expedite image critique, interpretation, enhance exposures, avoid repeat films, and most importantly improve positioning. Below references the 6 essential reasons nipple markers add value in positioning and image critique.

Hint: When applying a nipple marker to a protruding nipple, apply it around the protrusion of the nipple; do not flatten the nipple with the marker. If the nipple is flattened, the marker will pop off on one side when compression is applied.

6 Reasons Nipple Markers Add Value in Positioning and Image Critique:

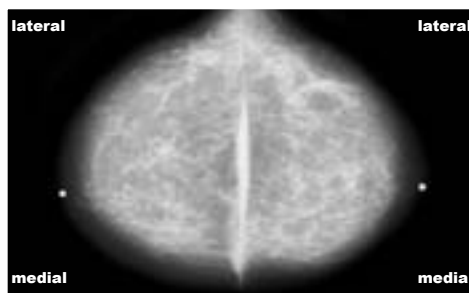

1. Identifies if lateral or medial tissue is missing on the image

A.



Nipples are not always naturally in the perfect position. On the CC view if the nipple points lateral, this indicates we are missing some lateral tissue, refer to exhibit A.

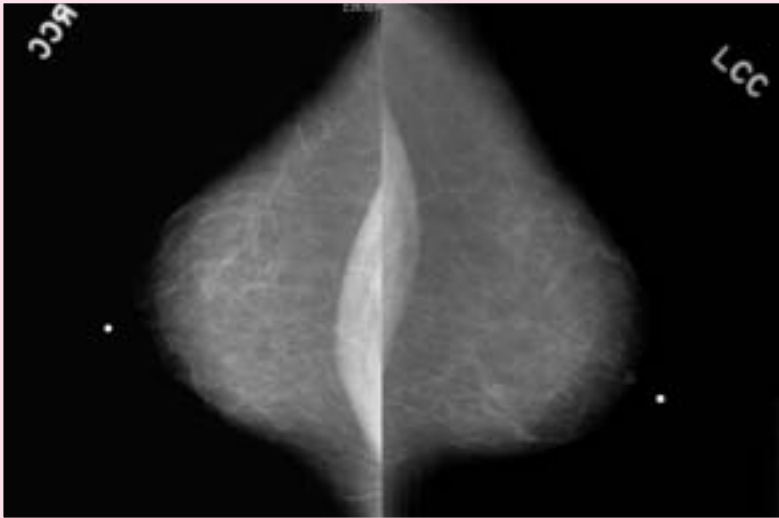
B.



Following the same guidelines, if the nipple is pointing medial, we are missing some medial tissue; refer to exhibit B. An important rule in image critique is to reference the nipple. Without a nipple marker it is more difficult and will often be overlooked during image critique.

When critiquing the CC view, you must answer the following questions:

C.



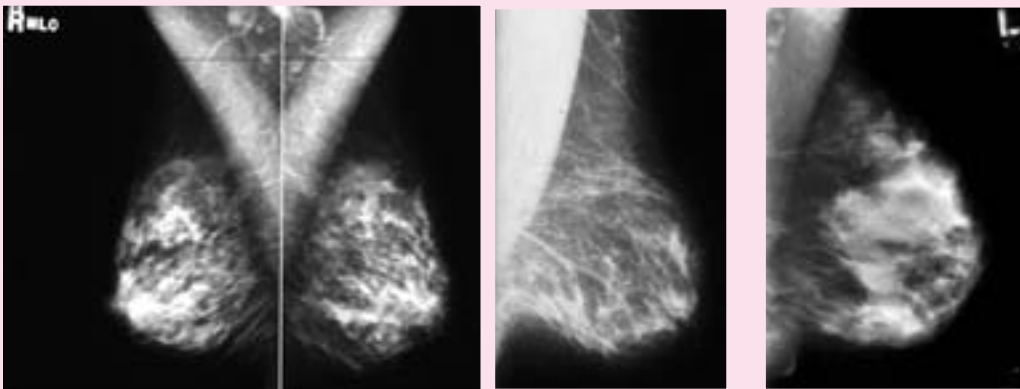
1. Is all the medial tissue imaged?
2. Is the nipple centered on the image?
3. Does the posterior nipple line measure to within 1 cm of the MLO view?

Without a nipple marker it would be harder to determine the answer to the questions above. Look at these two CC views in film exhibit C. In the right CC the nipple is centered. In the left CC the nipple is exaggerated medially which tells us that medial tissue is missing.

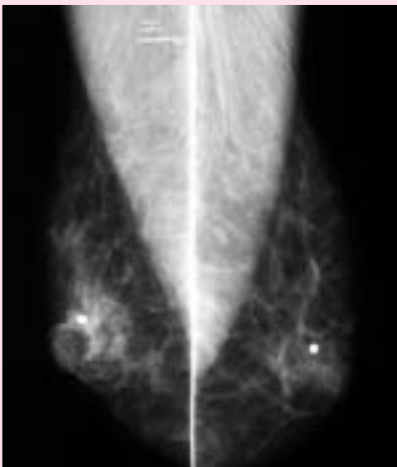
When critiquing the MLO view you must answer the following questions (refer to exhibit D):

1. Is the pectoral muscle wide superiorly with a convex anterior border? (*a convex margin is preferable to a concave margin.*)
2. Does the pectoral muscle extend to or below the posterior nipple line?
3. Are the deep and superficial tissues well separated?
4. Is the inframammary fold open?

D.



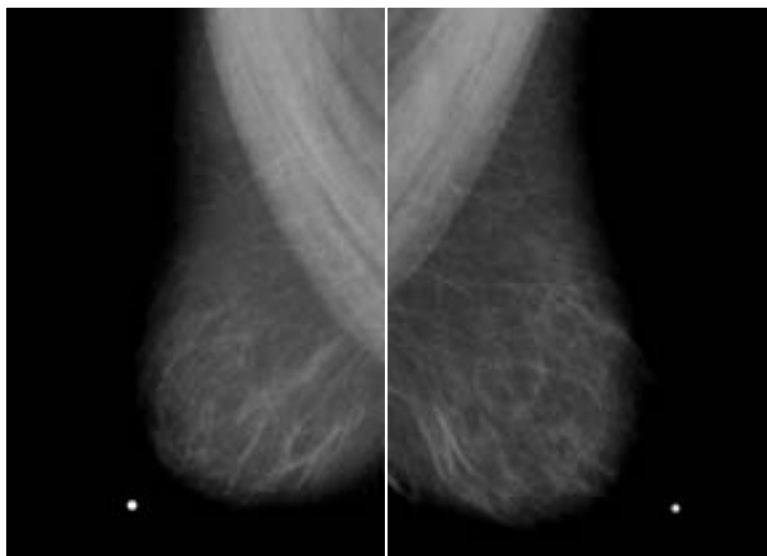E.



Look at the two MLO views in film exhibit E. The nipples in both breasts are rotated medially indicating that the deep and superficial tissues are not well separated and are overlapping the posterior fat.

2. Indicates suboptimal anterior compression and rotation of the nipple on the MLO view

F.

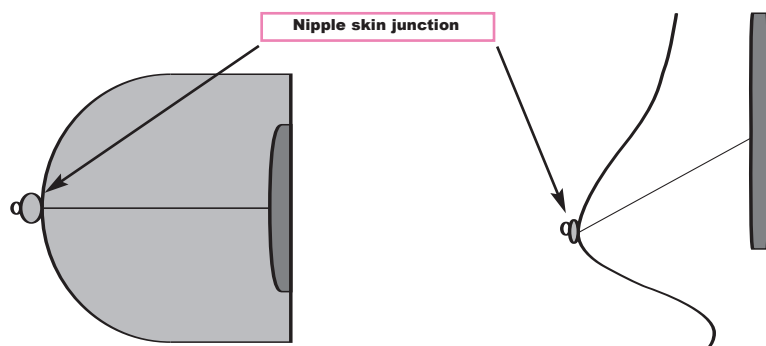


As you can see in the MLO views in exhibit F the pectoral muscle is large, the breasts are sagging and do not have adequate anterior compression.

On the MLO view we must image the pectoral muscle with a muscle pattern that is wide superiorly with a convex anterior border to the level of the nipple or further. This can be achieved with 80% of women. The pectoral muscle is the most difficult area to properly capture when positioning the MLO view. The larger or thicker the pectoral muscle, the more difficult it is to achieve adequate anterior compression. The nipple marker is an excellent reference during image critique and alerts us that anterior compression is compromised by the level of the nipple on the image. As a result the need for an anterior compression view is quickly identified. Similar to using your sense of touch to locate the nipple marker in the CC view, we use our hands while positioning the MLO view to mobilize, capture and secure the tissue prior to compression. The nipple marker is a valuable tool in this process. A nipple that is rotated medially on the MLO view is a good indication that the patient was not fully turned into the unit. A nipple that is rotated laterally on the MLO view indicates that the lateral tissue was not fully mobilized anterior and medial during positioning.

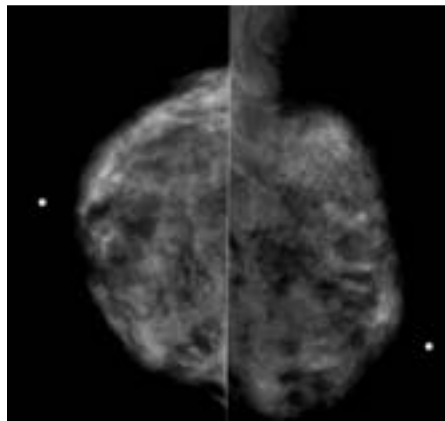
Hint: Never send films in for accreditation where the nipples are not centered on the CC view or are rotated on the MLO view. There is a misconception that you should not send images in for accreditation with nipple or skin markers. Films with skin markers are fully acceptable for accreditation.

3. A landmark for the posterior nipple line measurement tool



When measuring the posterior nipple line in the MLO and CC projections, the rule is that the CC view must measure within 1 cm of the MLO view (MLO drawn along the axis). A CC view that does not measure within 1 cm of the MLO view indicates that the entire breast is not imaged on the CC view. The measurement is made from the nipple skin junction. The nipple marker will not be the nipple skin junction on a protruding nipple, but will assist with locating the junction for proper measurement criteria. The measurement tool is based on today's very strict criteria and it sets a level of quality we want to achieve in order to optimize the technology. We need to consider how well we are using the technology available and what we can do to improve. We will not get the outcomes we want unless we optimize the technology available.

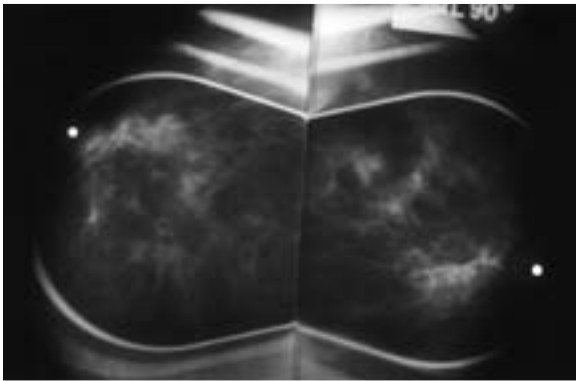
G.



You can see on the images in exhibit G the protruding nipple projects the nipple marker several cm from the actual nipple skin junction. The nipple marker will assist you in making an accurate measurement.

4. Helps to determine area for spot compression or spot compression magnification views

H.

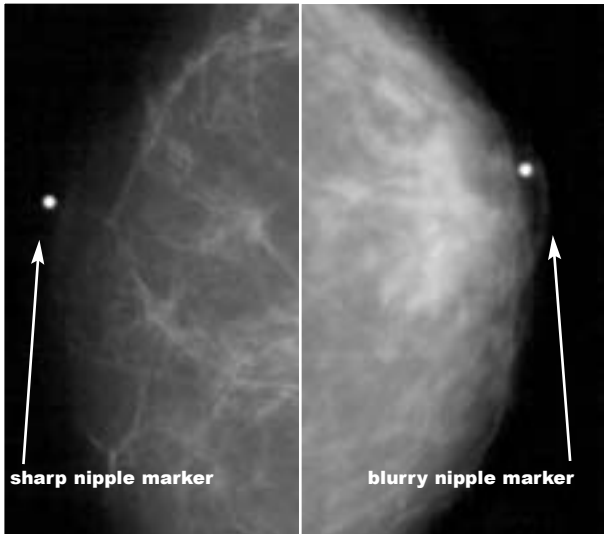


When a patient is called back because of an area of concern in the breast, a spot or spot magnification view is typically performed to work-up the area of concern. Having a nipple marker on the screening mammogram will assist the technologist performing the diagnostic views. The nipple marker on the screening mammogram is used in reference to the abnormality while performing and critiquing the diagnostic views. This is especially valuable when performing diagnostic views of a subtle abnormality.

The nipple marker is also valuable on the spot or spot magnification films for repositioning and referencing the area of interest and additional landmarks in the breast tissue in a difficult case. The measurements for the spot views are much easier, faster and accurate for the technologist with the use of a nipple marker.

5. Nipple markers help to determine motion

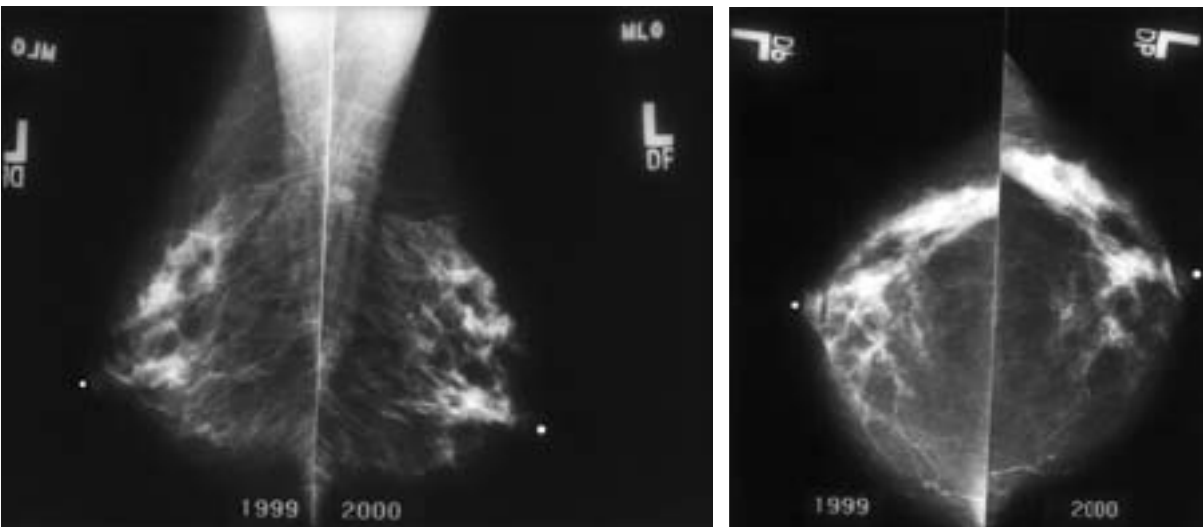
I.



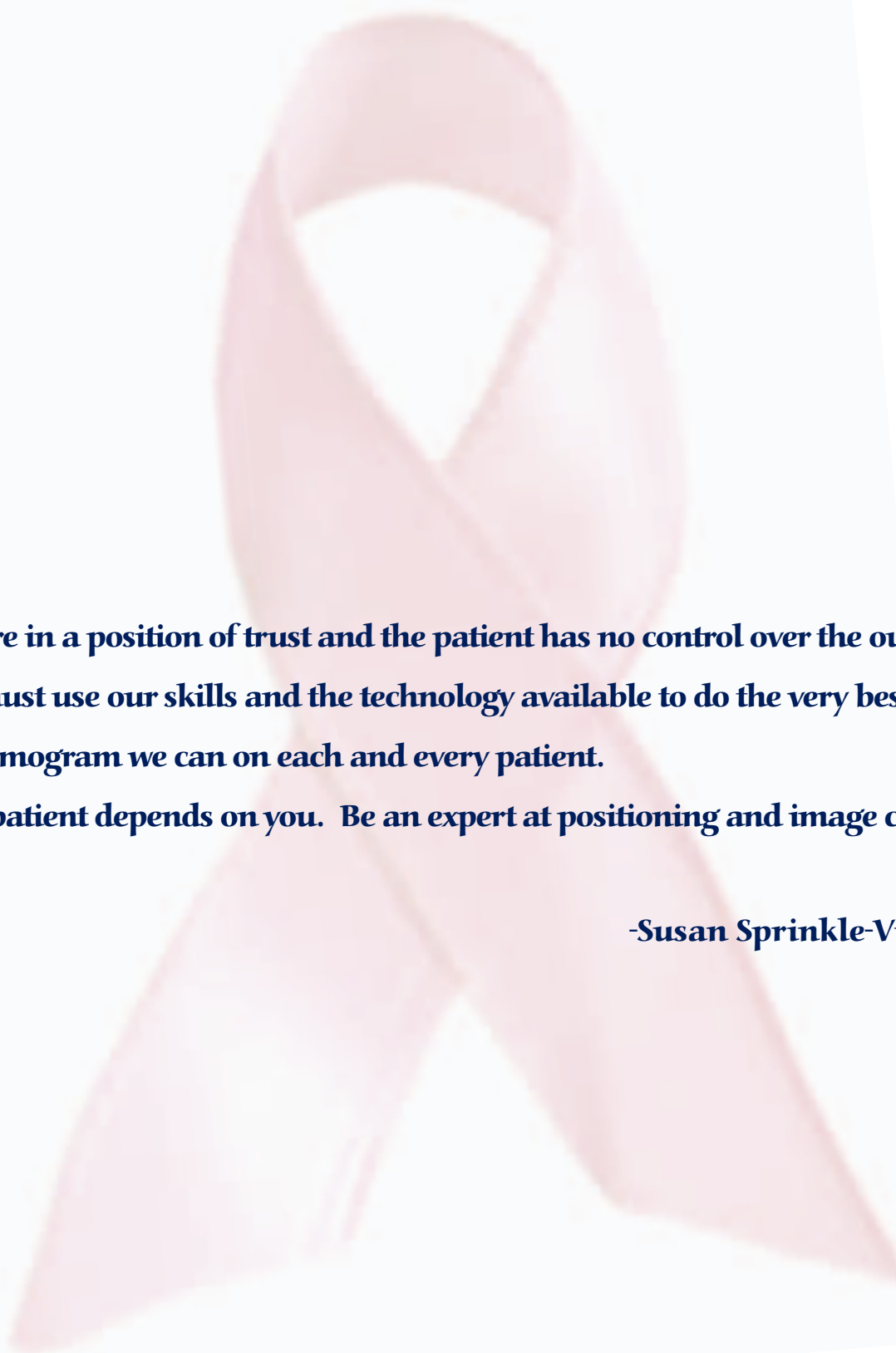
Motion blur on a mammogram is more detrimental to breast cancer detection than poor contrast. Even the most subtle motion can erase diagnostic information on the image. There are times it is questionable if the image has motion. We look for the double barrel effect and compare with the other images of the same study. The nipple marker is a valuable indicator of motion blur, see exhibit I. If you are questioning motion on your image look closely at your nipple markers, if they are blurry or oval you have answered your question.

6. Nipple markers assist us with comparing positioning from year to year or facility to facility

J.



It is important that positioning is optimal and consistent from year to year in order for the physician to use the very important comparison of mammograms to assist in the detection of breast cancer. How does the nipple marker assist from year to year? On the MLO view it helps by looking at the level of the nipple in comparison to the inframammary fold. On the CC view it helps by indicating if all the breast was properly included on the image and if the nipple has been centered properly from year to year.



**“We are in a position of trust and the patient has no control over the outcome.
We must use our skills and the technology available to do the very best
mammogram we can on each and every patient.**

Your patient depends on you. Be an expert at positioning and image critique.”

-Susan Sprinkle-Vincent

6 Reasons Nipple Markers Add Value in Positioning and Image Critique:

1. Identifies if lateral or medial tissue is missing on the image.
2. Indicates suboptimal anterior compression and rotation of the nipple on the MLO view.
3. A landmark for the posterior nipple line measurement tool.
4. Helps to determine area for Spot Compression or Spot Compression Magnification Views.
5. Nipple markers help to determine motion.
6. Nipple markers assist us with comparing positioning from year to year or facility to facility.



Routine Nipple Marking - A valuable tool in positioning and image critique A Universally Good Mammography Practice for Screen-film and Digital Examinations

BEEKLEY
CORPORATION

150 Dolphin Road, Bristol, CT 06010 Mailing: P.O. Box 369, Bristol, CT 06011 Tel: 1-800-233-5539 Fax: 1-800-735-1234 www.beekley.com

0507

May 2007, published by The Beekley Corporation